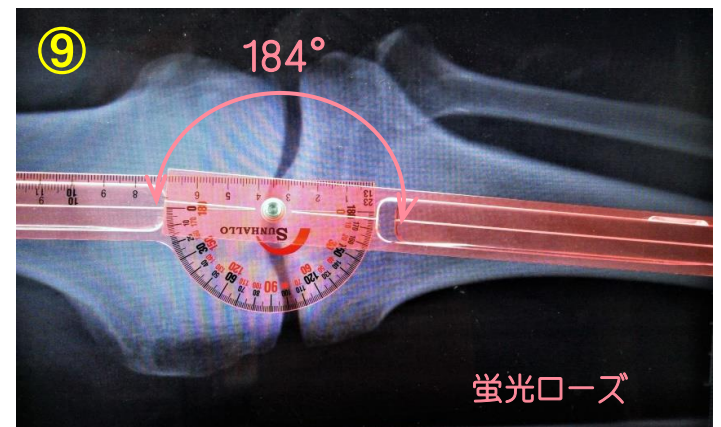
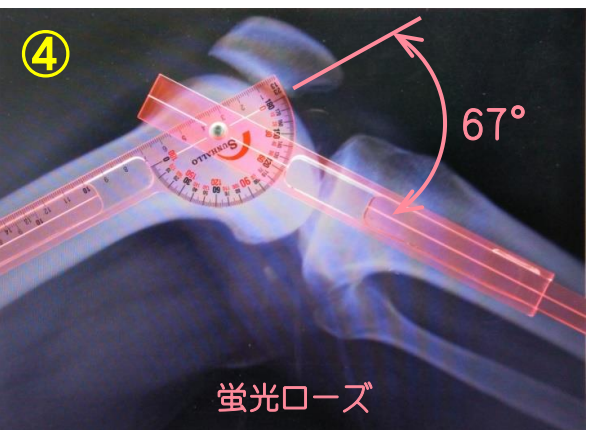
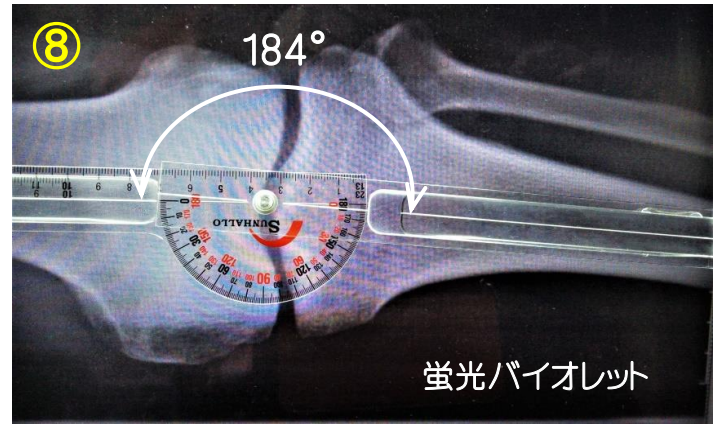
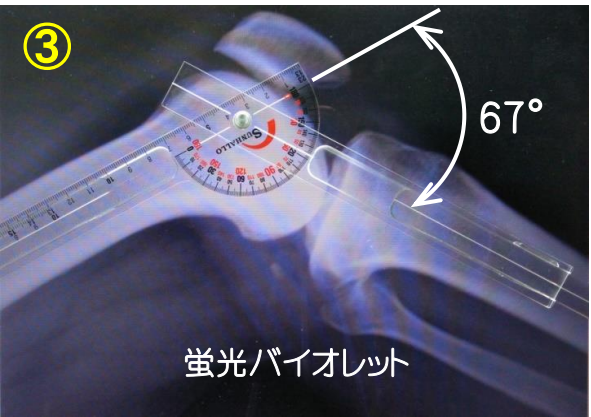
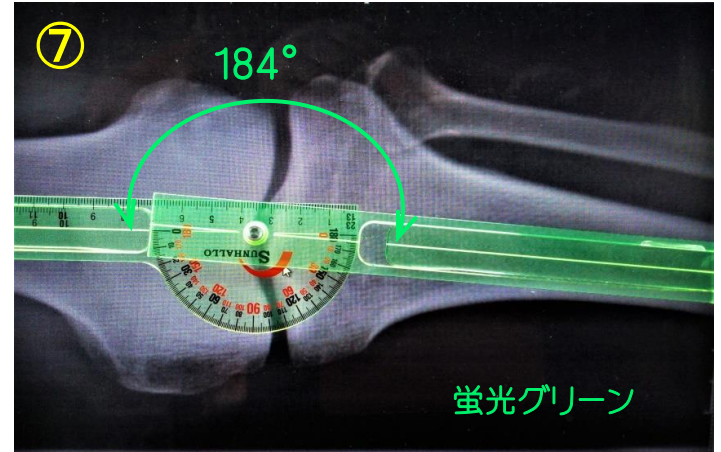
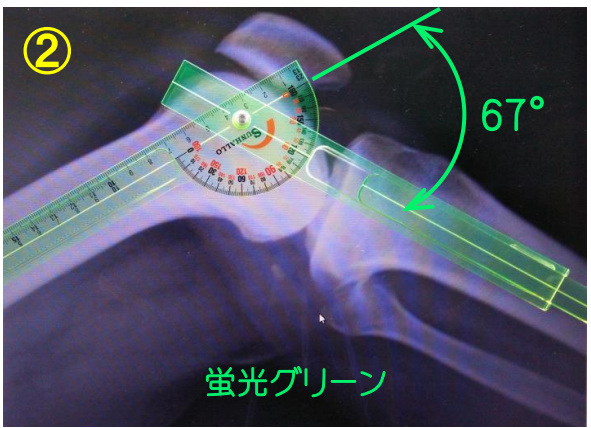
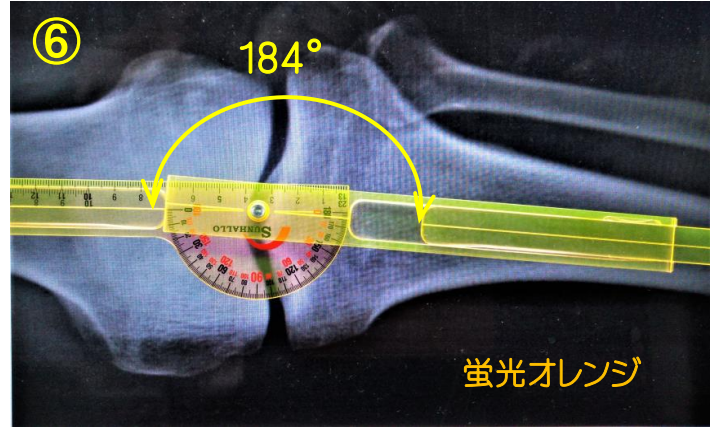
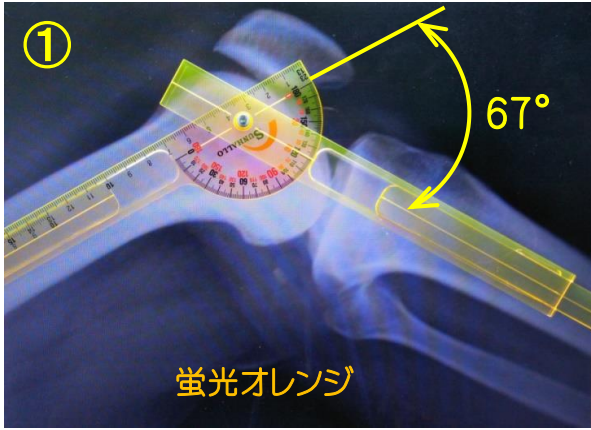


レントゲン写真とイクステンドゴニオメーター

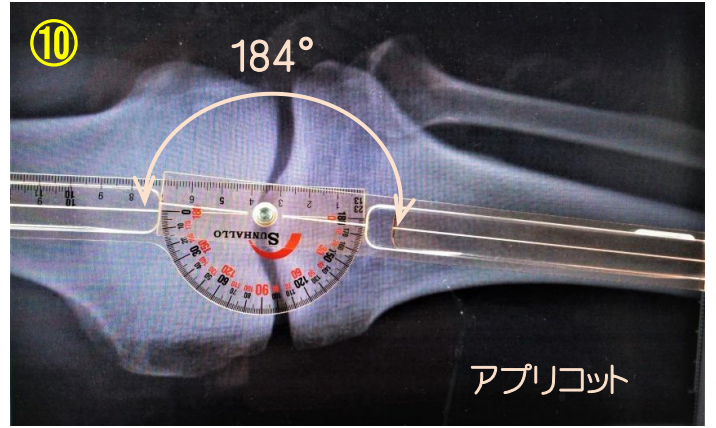
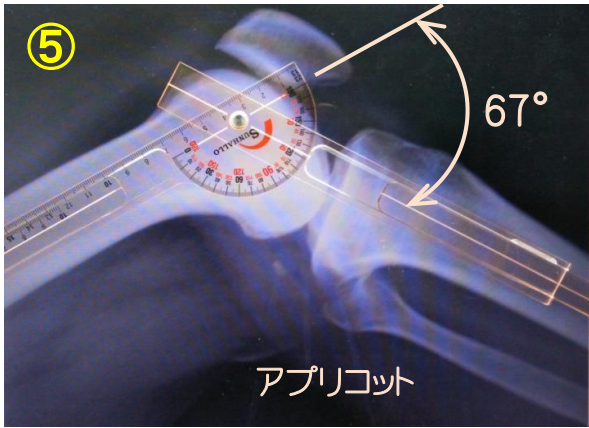
膝関節

屈曲角

FTA (Femoro-Tibial Angle)


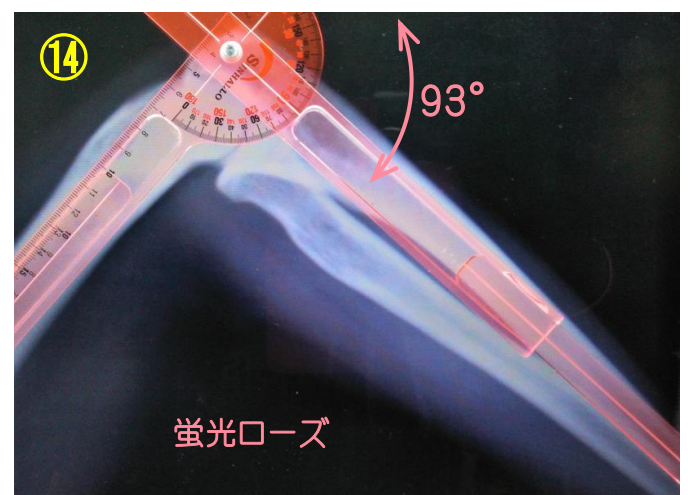

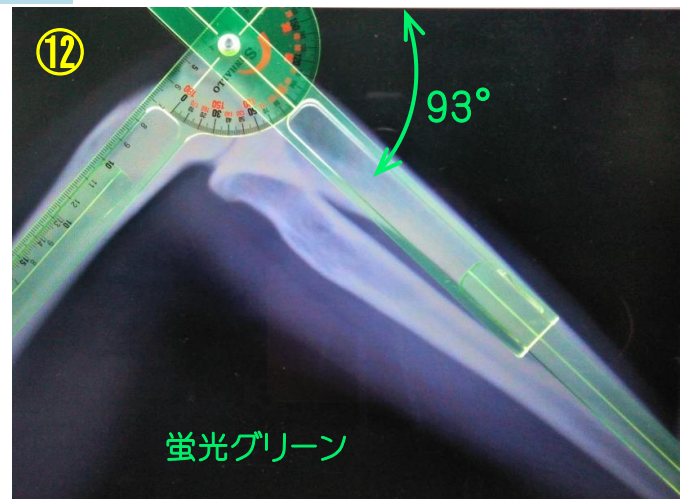
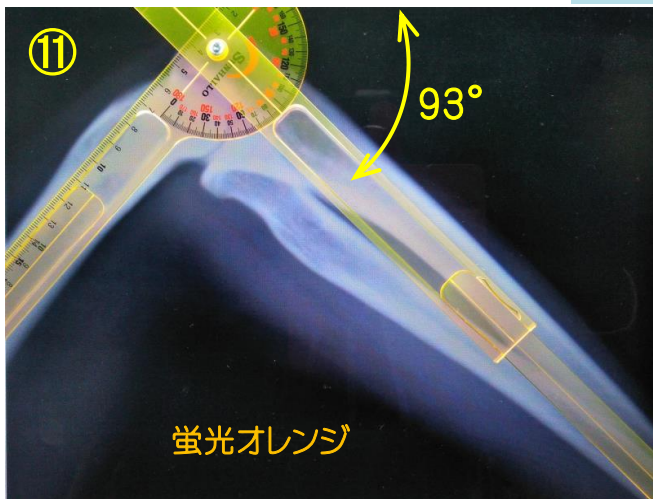


膝関節

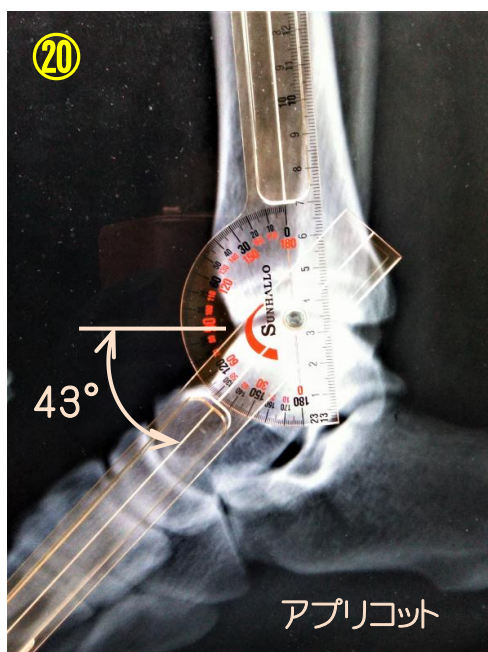
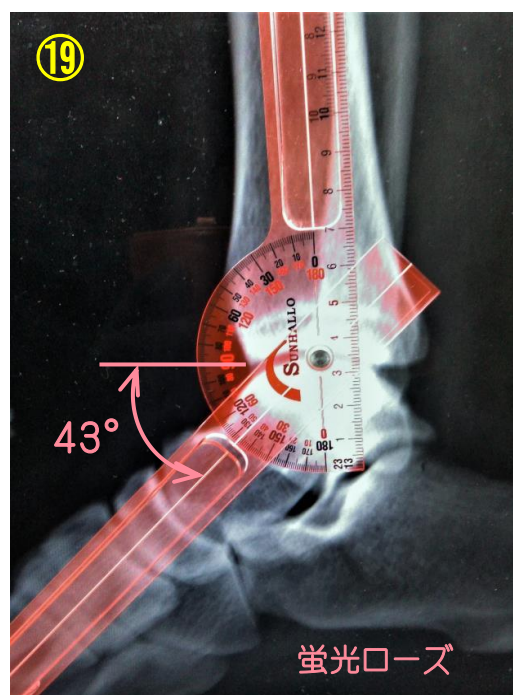
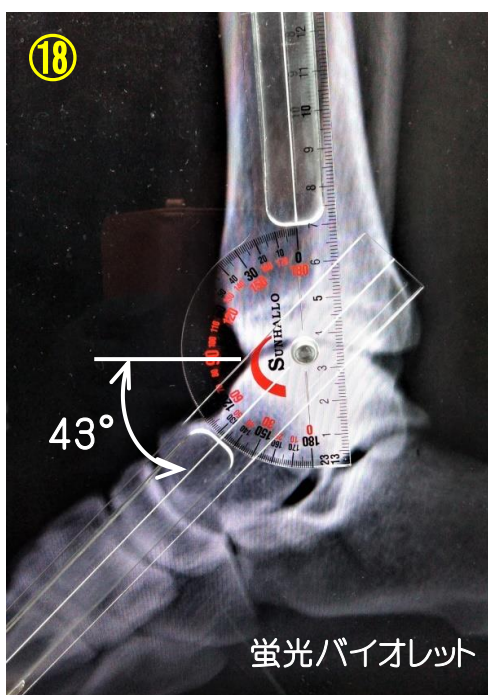
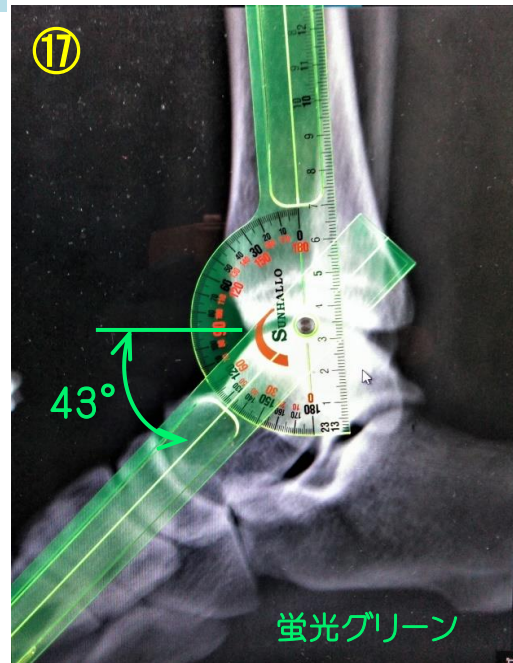
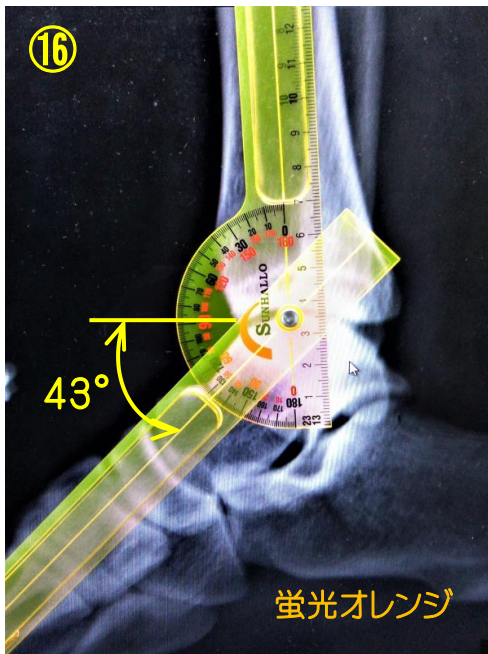


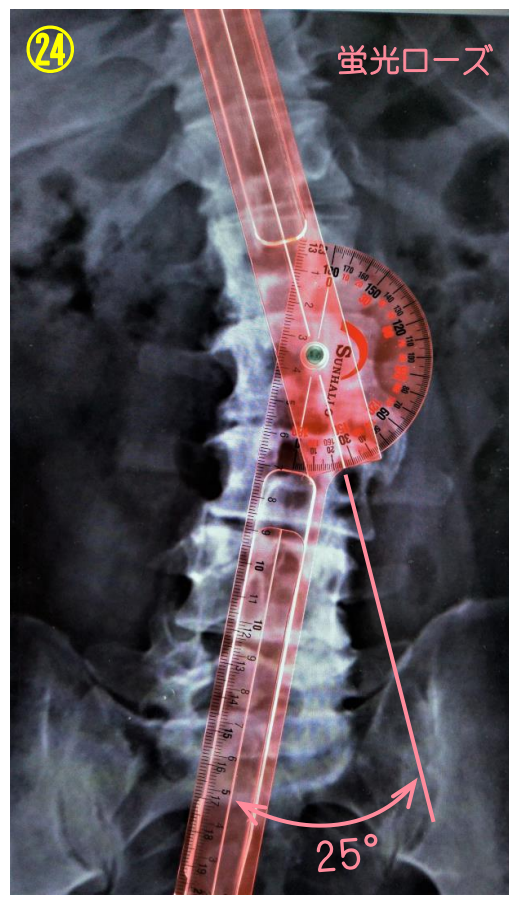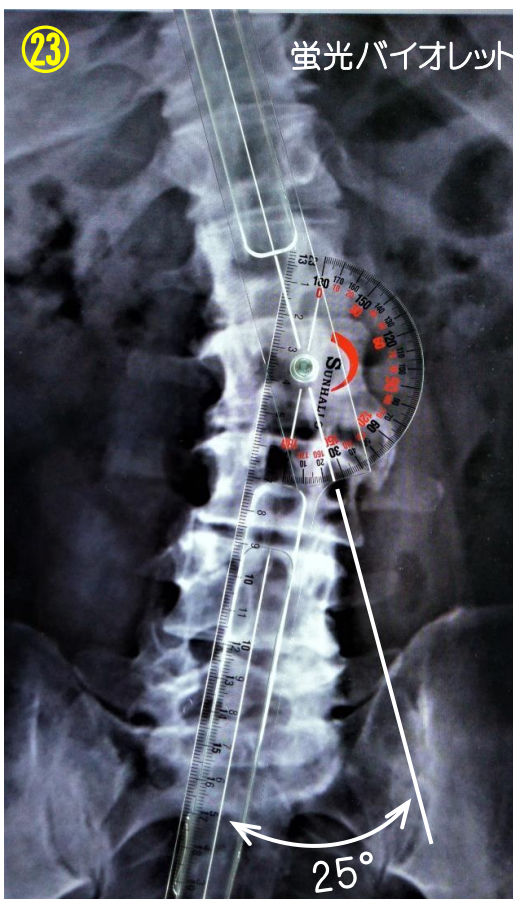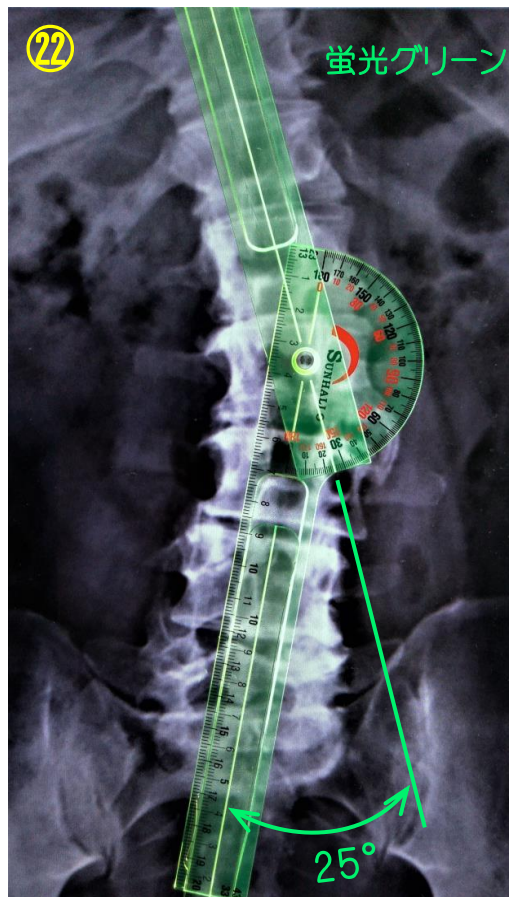
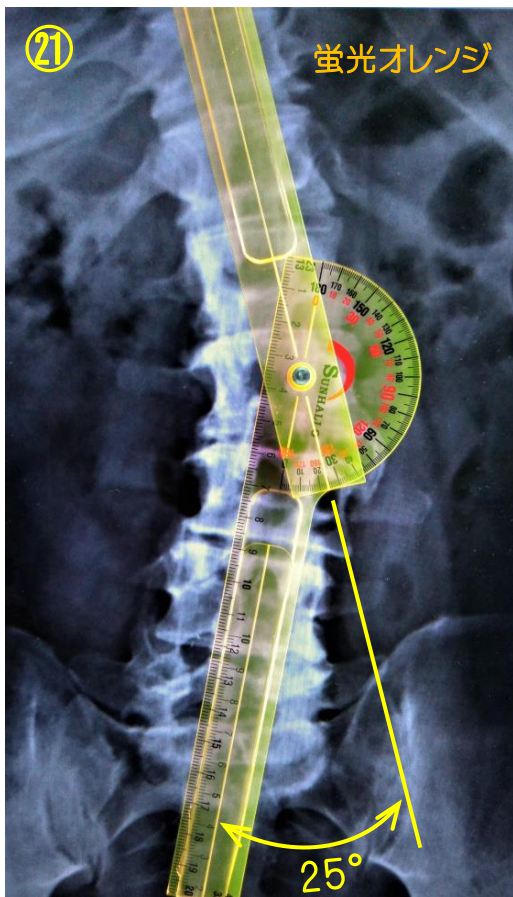
屈曲角

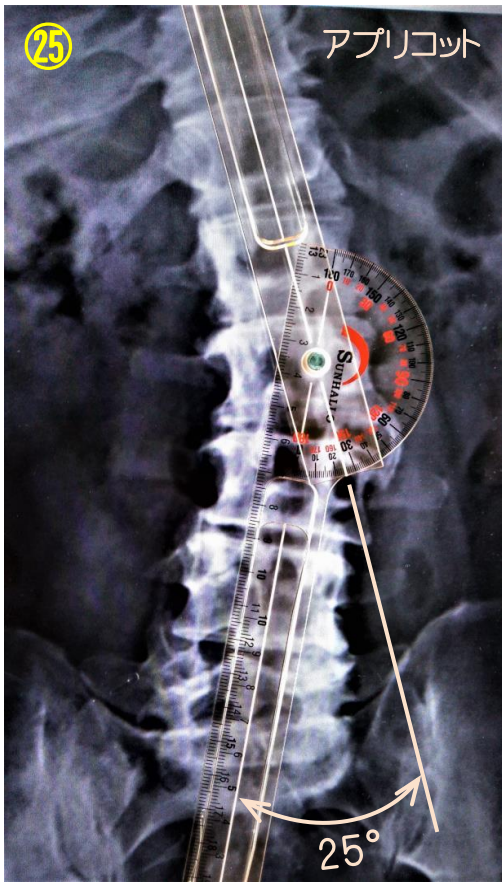肘関節



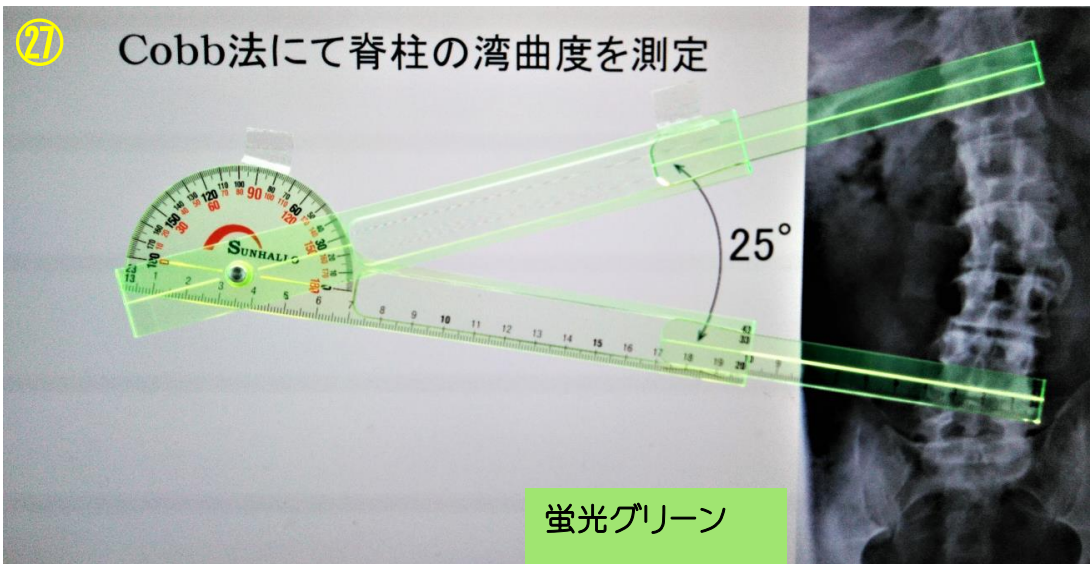
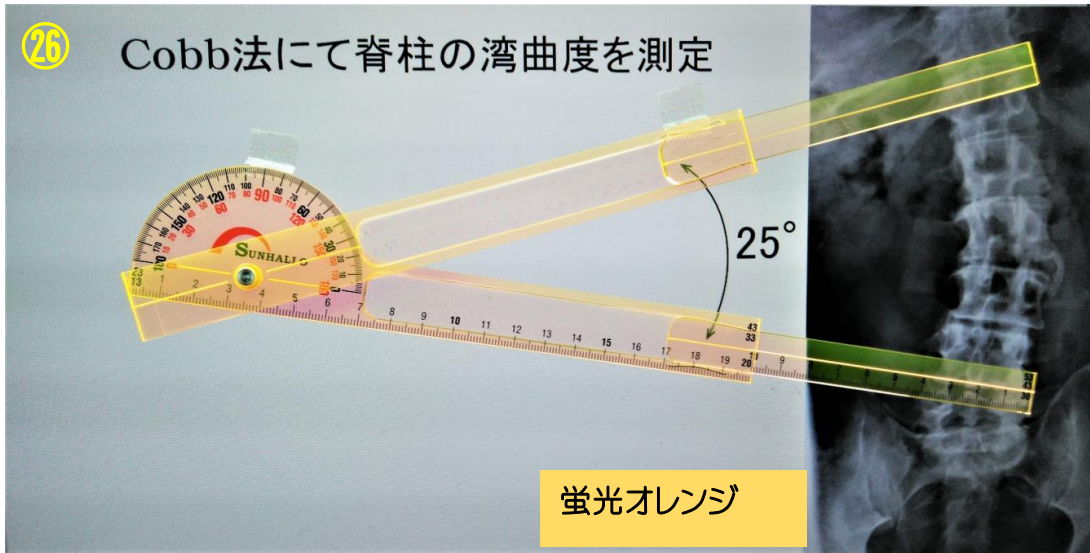
足関節





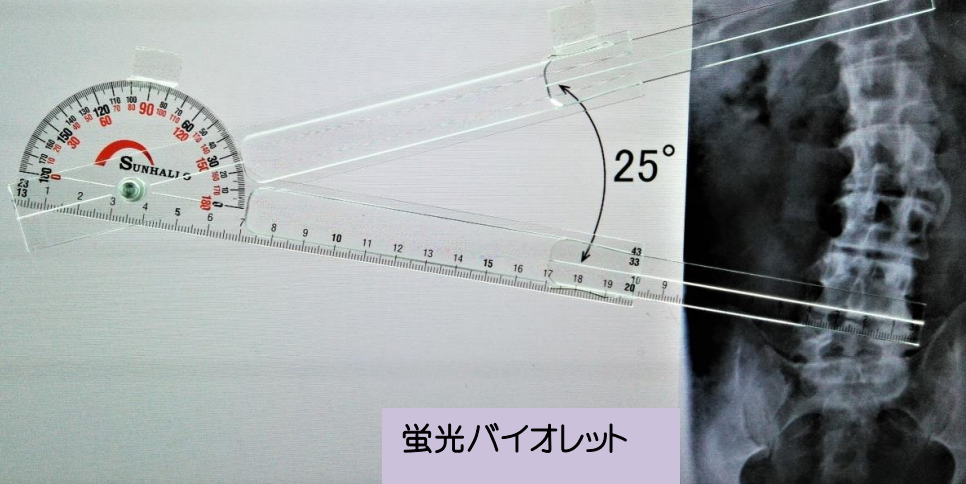


Cobb法による脊柱の湾曲度



28

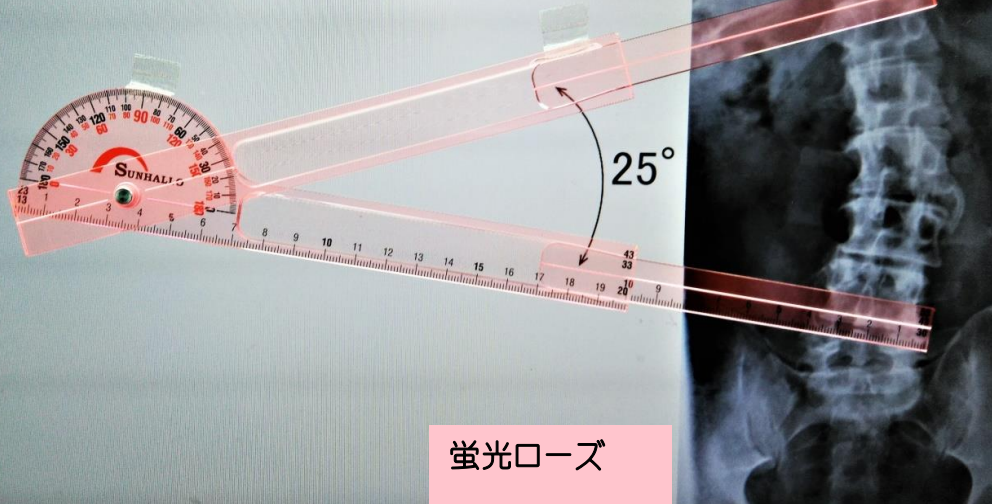
Cobb法にて脊柱の湾曲度を測定



蛍光バイオレット

29

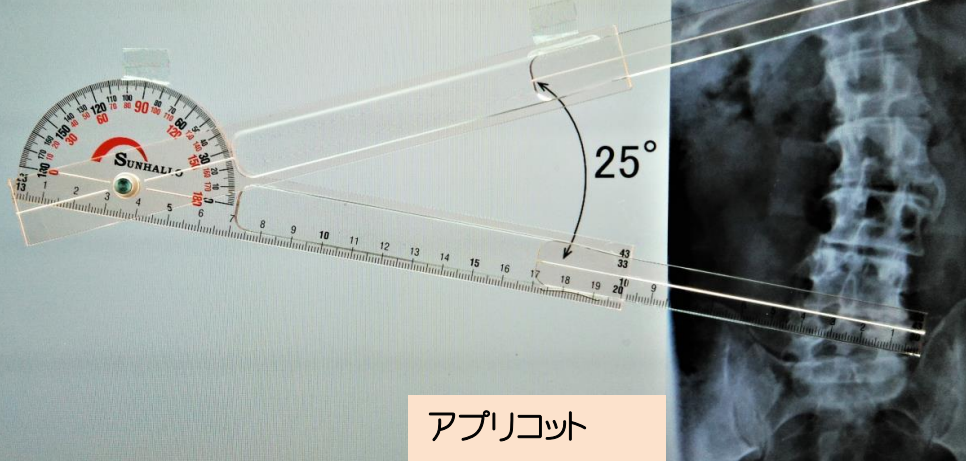
Cobb法にて脊柱の湾曲度を測定



蛍光ローズ

30

Cobb法にて脊柱の湾曲度を測定



アプリコット

大腿骨頸体角

